Upper Cervical Instability (UCI)

IN SYMPTOMATIC HYPERMOBILITY

Definitions

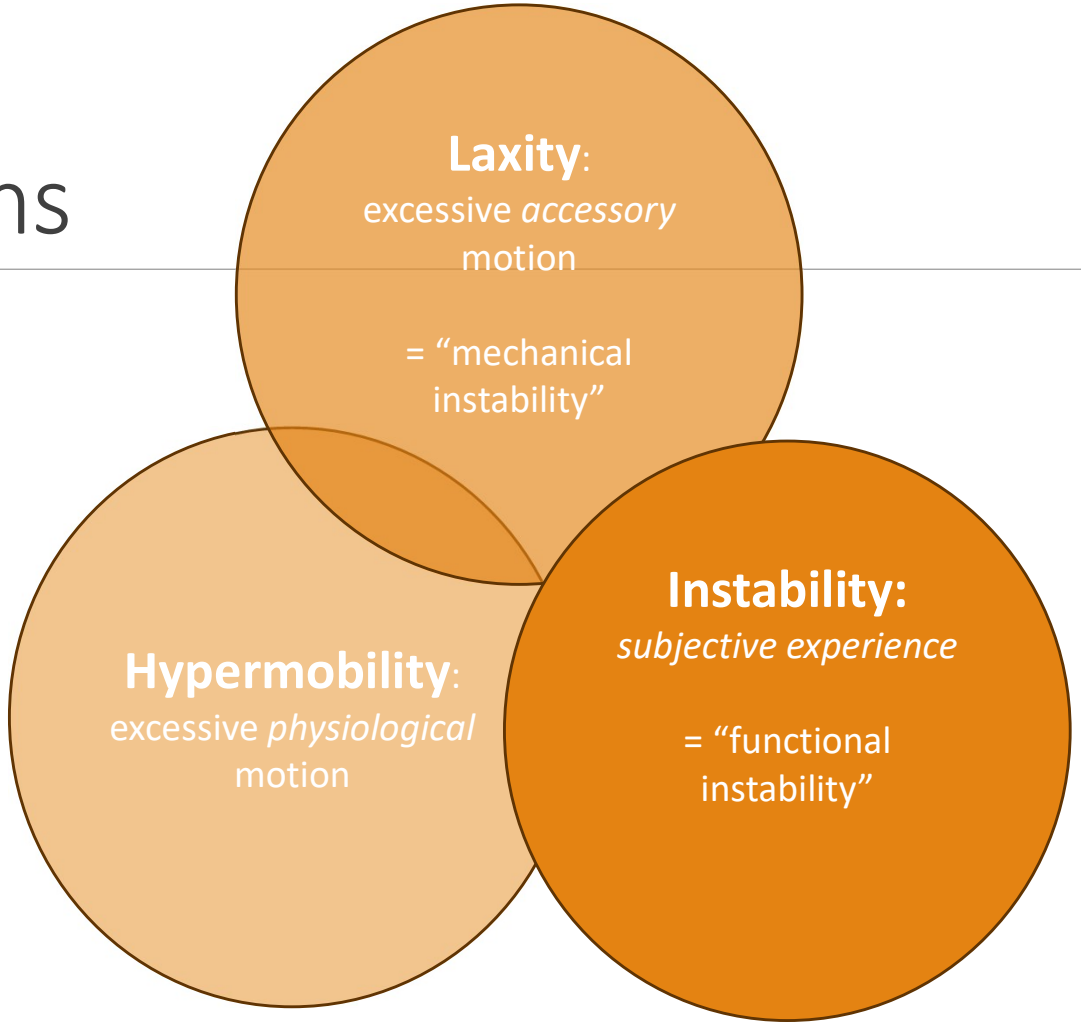

Hypermobility

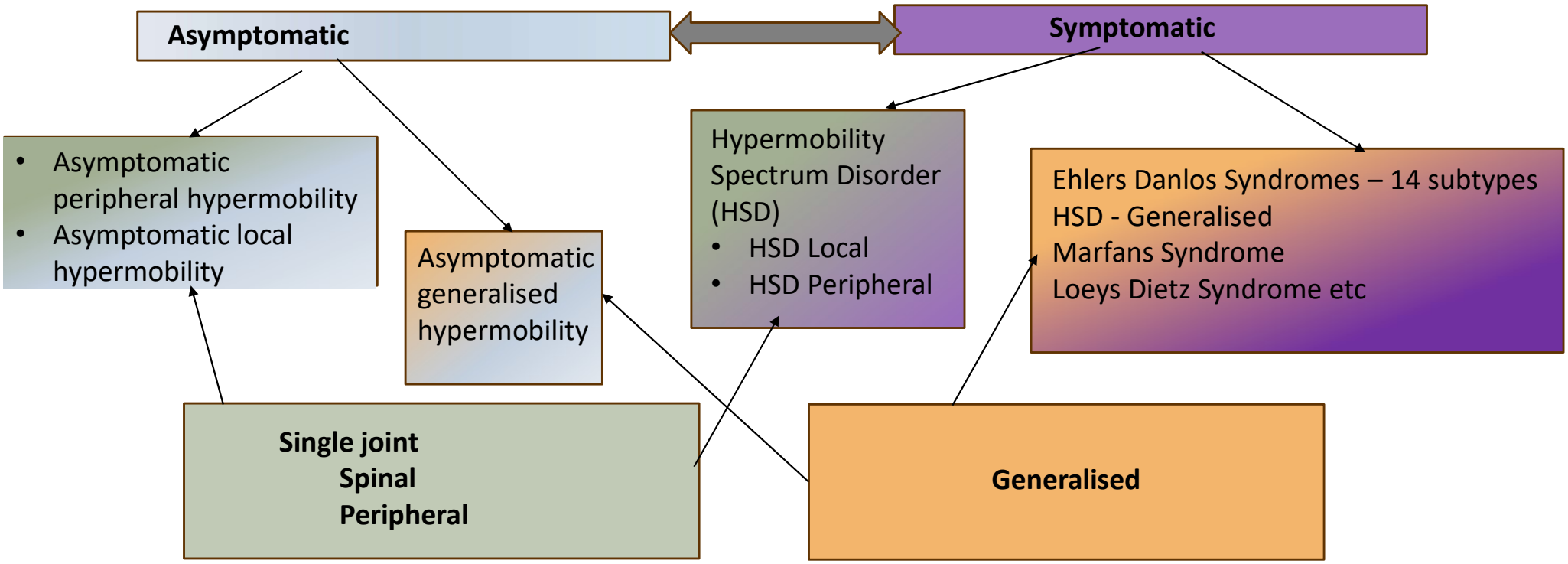

Hypermobility

Symptomatic

Ehlers Danlos Syndromes – 14 subtypes
HSD - Generalised
Marfans Syndrome
Loeys Dietz Syndrome etc

Generalised

Upper Cervical Instability

AAI = Atlantoaxial Instability
- Instability of the C12 articulations

CCI = Cranio cervical instability
- Generally refers to instability of the OC1 articulation
- Used by some to include both OC1 and C12 instability

UCI = Upper Cervical Instability
- Encompasses both CCI and AAI

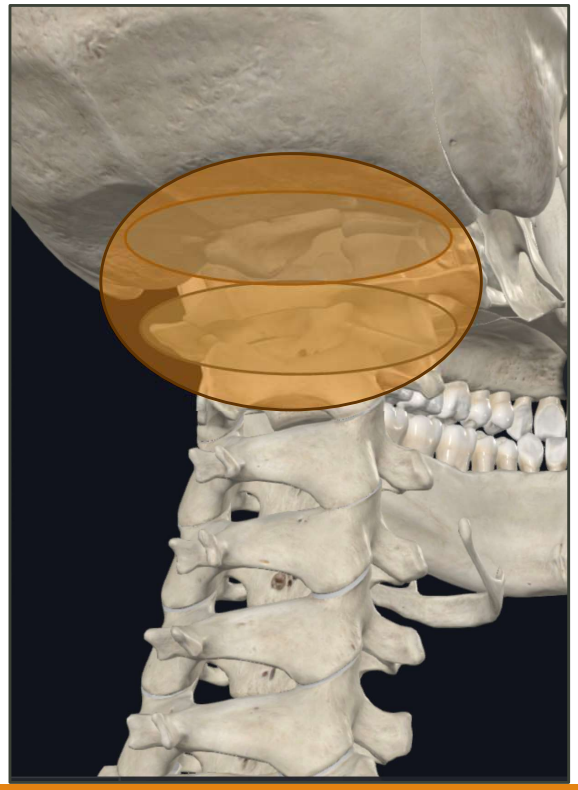

Upper Cervical Anatomy

Clinical Significance

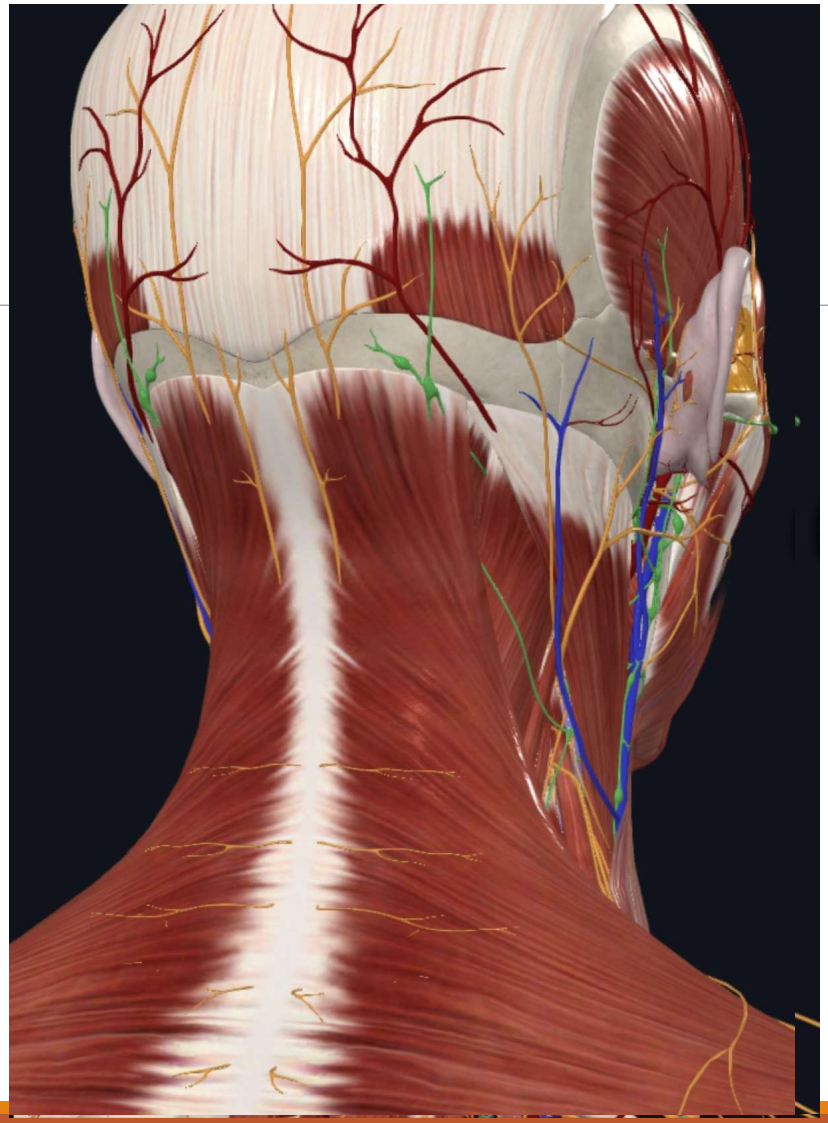

Research Review

1. Is there a correlation between cervical F/E ROM and generalised hypermobility
   Nicholson et al (2021)

2. Defining UCI radiologically
   Nicholson et al (2022)

3. Management guidelines
   Russek et al (2023)

4. Q&A

ELSEVIER
Physiotherapy
Physiotherapy 112 (2021) 150–157

Is there a relationship between sagittal cervical spine mobility and generalised joint hypermobility? A cross-sectional study of 1000 healthy Australians

Leslie L. Nicholson[a,*], Marnee J. McKay[b], Jennifer N. Baldwin[b,c], Joshua Burns[b,d], Winky Cheung[e], Sally Yip[e], Cliffton Chan[a]

La radiologia medica
https://doi.org/10.1007/s11547-023-01588-8
HEAD, NECK AND DENTAL RADIOLOGY

Reference values of four measures of craniocervical stability using upright dynamic magnetic resonance imaging

Leslie L. Nicholson[1] · Prashanth J. Rao[2,3] · Matthew Lee[4] · Tsz Ming Wong[5] · Regen Hoi Yan Cheng[5] · Cliffton Chan[1]

Presentation and physical therapy management of upper cervical instability in patients with symptomatic generalized joint hypermobility: International expert consensus recommendations

Leslie N. Russek[1,2*], Nancy P. Block[3], Elaine Byrne[4], Susan Chalela[5], Cliffton Chan[6], Mark Comerford[7,8], Nicole Frost[9], Sharon Hennessey[10], Ann McCarthy[4], Leslie L. Nicholson[11], Jason Parry[4,12], Jane Simmonds[4,13], Patricia J. Stott[14], Lucy Thomas[15], Julia Treleaven[7,15], Wendy Wagner[16] and Alan Hakim[12,17]

Research Review – Papers 1 & 2

Associate Professor Cliffton Chan

PhD, BPhysio(HonsI), GDMusic, GCEduStd (HighEd), DipSportsNutri

ELSEVIER

Physiotherapy 112 (2021) 150–157

Physiotherapy

Is there a relationship between sagittal cervical spine mobility and generalised joint hypermobility? A cross-sectional study of 1000 healthy Australians

Leslie L. Nicholson[a,*], Marnee J. McKay[b], Jennifer N. Baldwin[b,c], Joshua Burns[b,d], Winky Cheung[e], Sally Yip[e], Cliffton Chan[a]

CrossMark

La radiologia medica
https://doi.org/10.1007/s11547-023-01588-8

HEAD, NECK AND DENTAL RADIOLOGY

Check for updates

Reference values of four measures of craniocervical stability using upright dynamic magnetic resonance imaging

Leslie L. Nicholson[1] · Prashanth J. Rao[2,3] · Matthew Lee[4] · Tsz Ming Wong[5] · Regen Hoi Yan Cheng[5] · Cliffton Chan[1]

Is there a relationship between sagittal cervical spine mobility and generalised joint hypermobility? A cross-sectional study of 1000 healthy Australians

Leslie Nicholson, Marnee McKay, Jennifer Baldwin, Joshua Burns, Winky Cheung, Sally Yip and **Cliffton Chan (PhD)***

*Associate Professor in Physiotherapy & Head of Anatomy, Faculty of Medicine, Health and Human Sciences, Macquarie University

Scope of the Problem

Excessive cervical or upper cervical motion

MACQUARIE University

Instability
42%

(Milby et al. 2008)

Trauma

RA & AS
10-70%

(Martini et al. 2015)

Arthritis

DS
9-71%

Karol et al. 1996



EDS
5-66%

OI
25-37%

Genetics

What's the Gap?

MACQUARIE University

- Wide prevalence presented due to a lack of standardised measure for cervical, and upper cervical, hypermobility
- Only 1 assessment tool, Rotes-Querol Scale, measures cervical spine hypermobility with lateral flexion and rotation comprising one of ten points
- Normative ranges for cervical mobility (20-50yrs) are documented but not the prevalence of cervical hypermobility in general population and whether it's an isolated condition or manifestation of Generalised Joint Hypermobility (GJH)

Aims of this study

MACQUARIE University

1. To determine whether people with GJH also have cervical hypermobility

2. To determine which features (age, sex, ethnicity, GJH classification/extent) contribute to variability in sagittal cervical range

3. To establish cut-offs for sagittal range hypermobility across the lifespan for clinical use when assessing cervical instability

Methods

University of Sydney HREC Approval 2013/640

- Incepted 1000 healthy individuals aged 3-101 years
- Cervical ROM (CROM) - inclinometer
- Generalised Joint Hypermobility – Beighton Score
- Cut-off for Cervical Spine HM – uppermost 5% of flexion and extension for each decade

Statistical Analysis

MACQUARIE University

- Descriptive analysis, with t-tests performed for sex differences
- Correlation analysis conducted using Spearman's rho (ρ), and Pearson's correlation coefficient (r)
- Stepwise multiple regression determined which variables explained the variability in total CROM and flexion and extension range.
- The uppermost 5% flexion and extension cervical ranges for males and females in each decade were identified

Normative Values for Cervical Spine

Hypermobility & Flexion and Extension Ranges

MACQUARIE University

Table 1

Summary of GJH data and cervical mobility using age and gender group breakdown with independent t-test resu

Age ranges (years)	Beighton score mean (SD)		Flexion	Extension
	6% GJH			
	M	F		
3–9 (n = 135)	2.1 (1.5)	2.4 (1.9)		
10–19 (n = 162)	1.1 (1.3)	2.0 (1.6)		
20–29 (n = 100)	1.2 (1.3)	1.6 (1.6)		
30–39 (n = 100)	0.6 (0.9)	1.1 (1.5)	>	<
40–49 (n = 99)	0.3 (0.7)	1.0 (1.4)		
50–59 (n = 100)	0.2 (0.6)	0.5 (0.8)		
60+ (n = 286)	0.0 (0.2)	0.3 (0.7)		

M: male; F: female; SD: standard deviation; *denotes $p < 0.05$.
#Independent t-test.

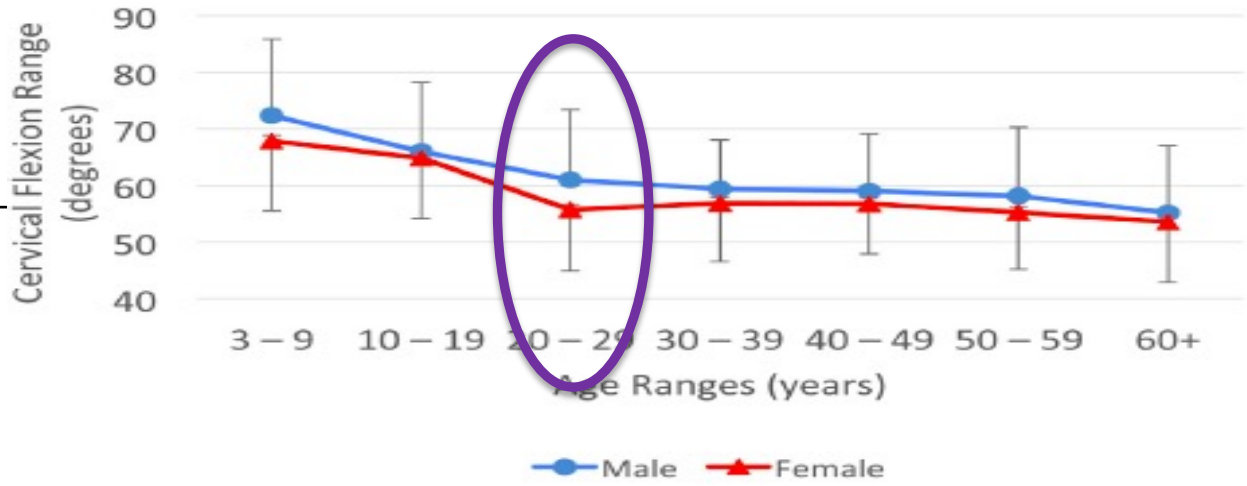
Cervical Flexion Range (degrees)
90
80
70
60
50
40
3 – 9
10 – 19
20 – 29
30 – 39
40 – 49
50 – 59
60+
Age Ranges (years)
Male
Female

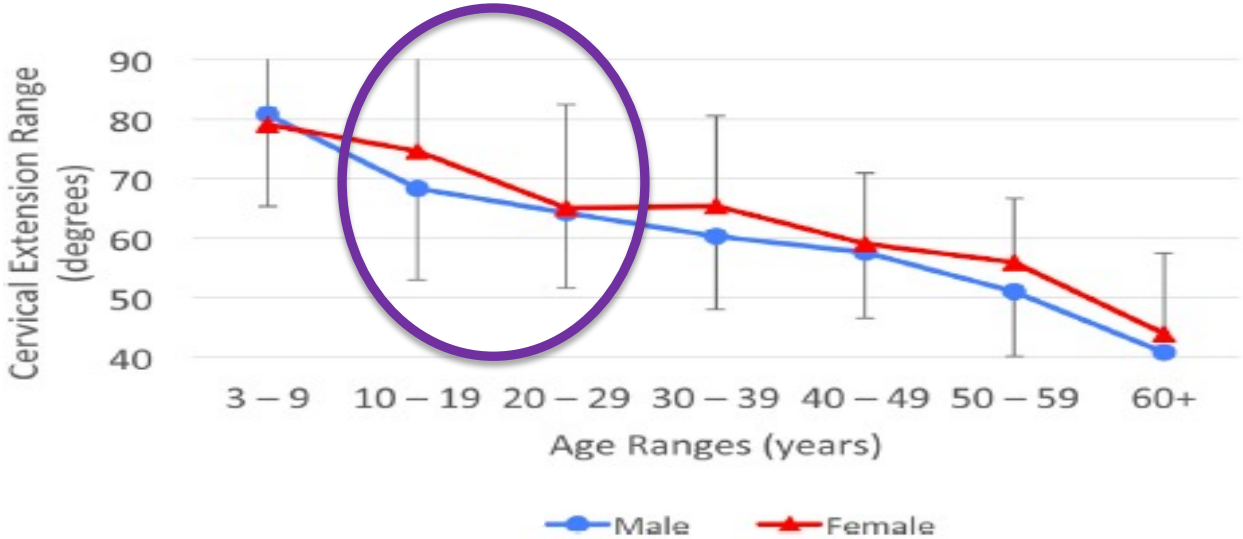
Cervical Extension Range (degrees)
90
80
70
60
50
40
3 – 9
10 – 19
20 – 29
30 – 39
40 – 49
50 – 59
60+
Age Ranges (years)
Male
Female

Correlations

Spearman's rho - GJH and sex/ethnicity/age

Correlations	Spearman's Rho
Beighton score (as a continuous measure)	
Cervical flexion	0.29**
Cervical extension	0.50**
Sex	0.17**
Ethnicity	0.09*
Age	−0.54**
Beighton score (Singh *et al.* (2017) classification)	
Cervical flexion	0.12**
Cervical extension	0.14**
Sex	N/A
Ethnicity	0.06
Age	N/A

* $p<0.01$.
** $p<0.001$.

Strength of correlation (ρ)

< 0.30	- negligible
0.30–0.49	- low
0.50–0.69	- moderate
0.70–0.89	- high
>0.90	- very high

Correlations

Pearson's r - Cervical Sagittal Range and Sex

Correlations	Correlation coefficient
Cervical flexion	
†Cervical extension	0.44**
Gender	−0.10*
Ethnicity	0.03
†Age	−0.41**
Cervical extension	
Gender	0.07
Ethnicity	0.09*
†Age	−0.70**

† Pearson's r was used for correlations between cervical mobility and age, all other correlations were calculated using Spearman's Rho.

* $p<0.01$.

** $p<0.001$.

Strength of correlation (r)

< 0.30	- negligible
0.30–0.49	- low
0.50–0.69	- moderate
0.70–0.89	- high
>0.90	- very high

Variance

Stepwise multiple regression

MACQUARIE University

Total Cervical ROM

- **Age and extent of GJH together,** explained for 49% of the variability

Cervical Extension ROM

- **Age, sex and extent of GJH together**, explained 51% of the variability

Cervical Flexion ROM

- **Age, sex and extent of GJH together**, explained 19% of the variability

Cervical Hypermobility Cut-offs

MACQUARIE University

Recommendations on cut-off for cervical sagittal hypermobility with reference to age and gender.

Age ranges (years)	CROM considered as hypermobile (cut-off for top 5%)			
	Flexion (°)		Extension (°)	
	Males	Females	Males	Females
3–9	96	90	105	110
10–19	85	81	91	100
20–29	75	75	82	95
30–39	75	73	80	87
40–49	75	73	75	80
50–59	75	73	70	73
60-69	75	70	60	72
70-70	75	70	57	63
80-101	68	66	52	55

Limitations & Research Directions

MACQUARIE University

- Limited to the “healthy” Australian population, predominantly Caucasians
- Cross-sectional study - changes in mobility over the lifespan are reported as group means
- The uppermost 5% of cervical mobility as a cut-off to determine hypermobility is statistically correct, it may be an under- or over-estimation for clinical purposes

Key Messages

MACQUARIE University

- People with GJH have significantly more spinal mobility in the sagittal plane (not instability)
- Age and extent of GJH highly influence total cervical and cervical extension ROM
- Greater loss in extension ROM than flexion, with a trend of the greatest loss of cervical ROM in the 2nd and 3rd decades of life

References

MACQUARIE University

- Martini, R. P., & Larson, D. M. (2015). Clinical evaluation and airway management for adults with cervical spine instability. Anesthesiology clinics, 33(2), 315-327.
- Milby, A. H., Halpern, C. H., Guo, W., & Stein, S. C. (2008). Prevalence of cervical spinal injury in trauma. Neurosurgical focus, 25(5), E10.
- Pimentel, L., & Diegelmann, L. (2010). Evaluation and management of acute cervical spine trauma. *Emergency Medicine Clinics*, *28*(4), 719.
- Russek, L. N., Block, N. P., Byrne, E., Chalela, S., Chan, C., Comerford, M., ... & Hakim, A. (2023). Presentation and physical therapy management of upper cervical instability in patients with symptomatic generalized joint hypermobility: International expert consensus recommendations. *Frontiers in Medicine*, *9*, 4020.

Thank you

Reference value of four measures of craniocervical stability using upright dynamic MRI

LL Nicholson, P Rao, M Lee, TM Wong, RHY Cheng, and Cliffton Chan*

*Associate Professor, PhD, Faculty of Medicine, Health and Human Sciences, Macquarie University

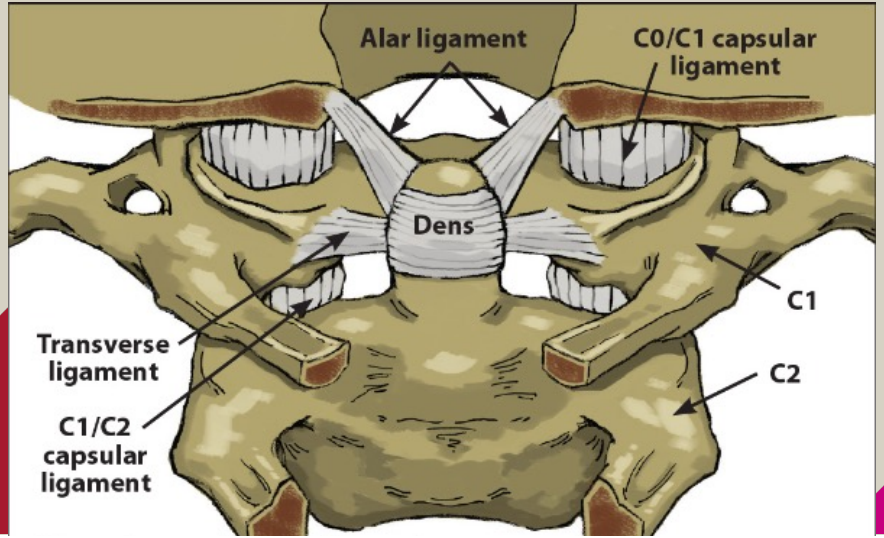

https://www.caringmedical.com/prolotherapy-news/upper-cervical-instability-affects-brain-stem/

Symptoms

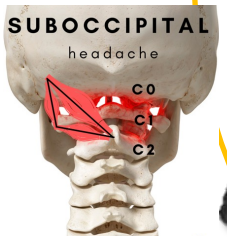



Russek et al. 2023

Continuing the Quest

MACQUARIE University

- Need for standardised hypermobility measures of upper cervical spine

- In addition to neutral position, but also in flexion and extension ranges

This study aimed to determine:

MACQUARIE University

1) A reliable measurement protocol to detect the presence of CCI using upright dynamic MRI,
2) The reference ranges in three positions (maximal flexion, maximal extension and neutral).
3) Whether differences exist in the extent of motion between neutral to flexion and neutral to extension, and the correlation of age and sex with these measures
4) The proportion of false-positive identifications of CCI.

Upright Dynamic MRI

FONAR UPRIGHT Multi-Position™ MRI (0.6 Tesla)

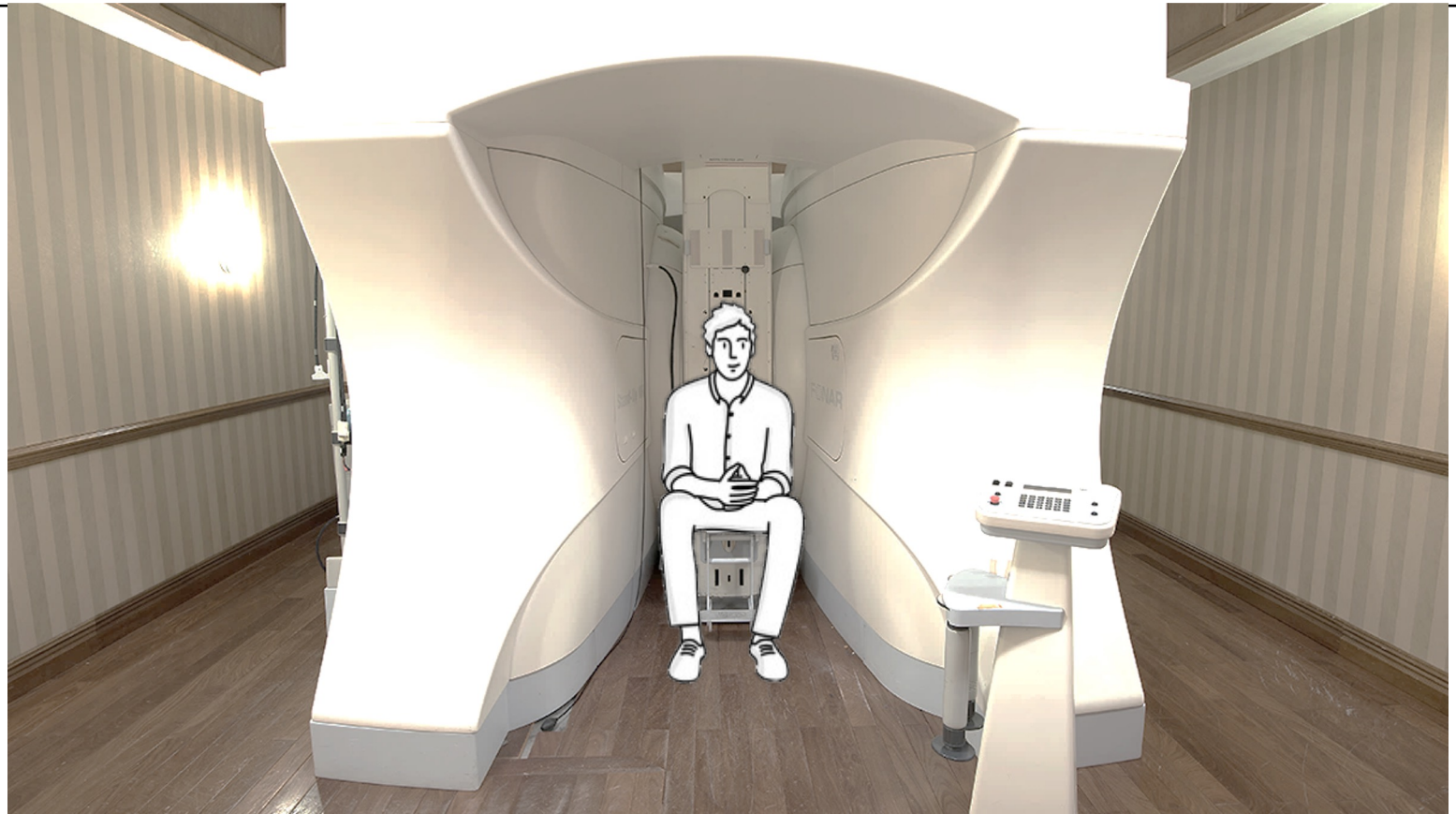

Upright Dynamic MRI

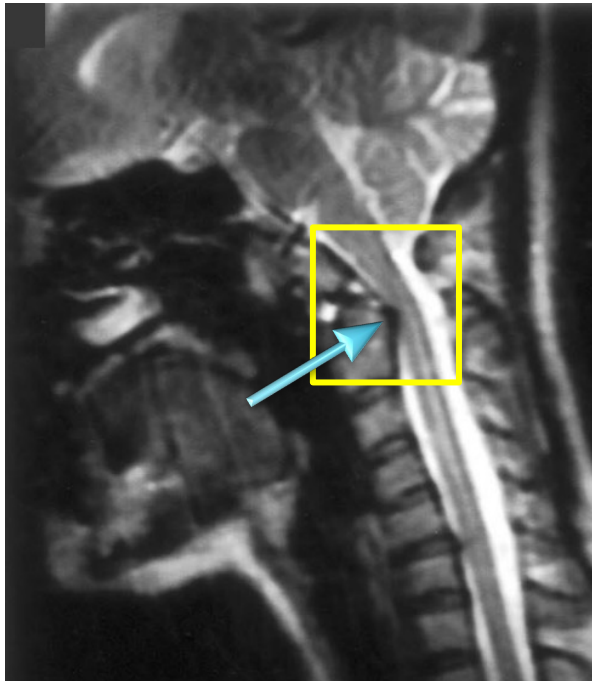

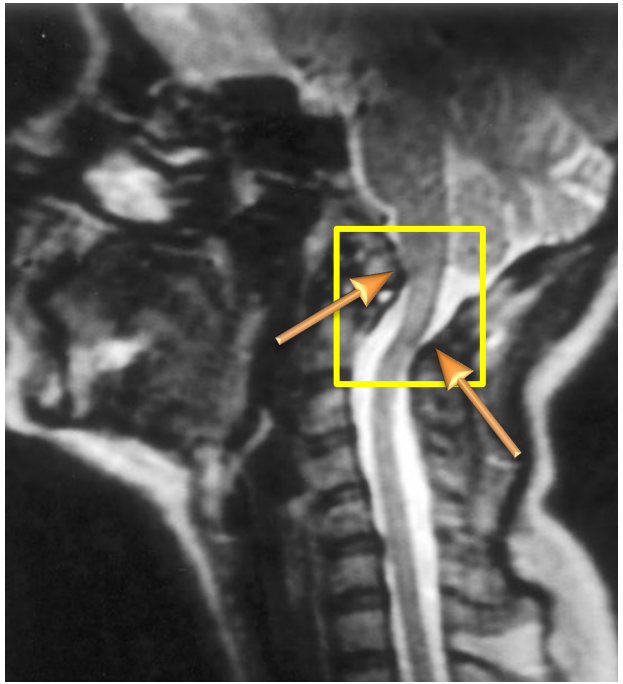

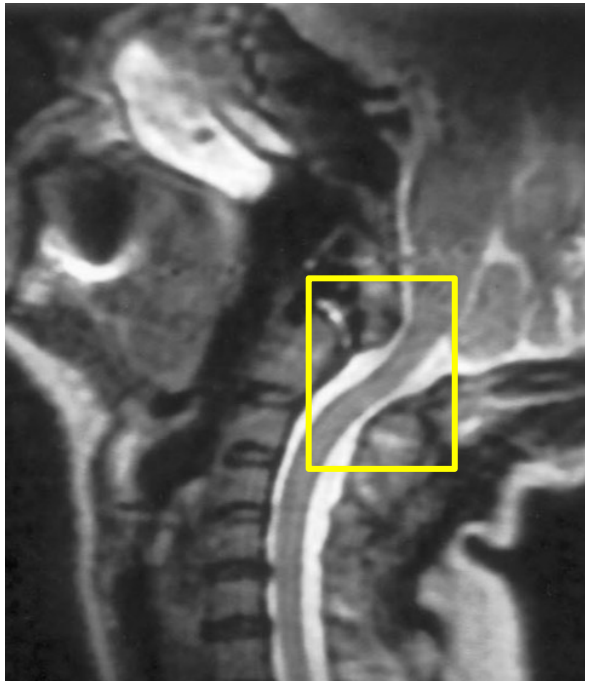

Most Common CCI Measures

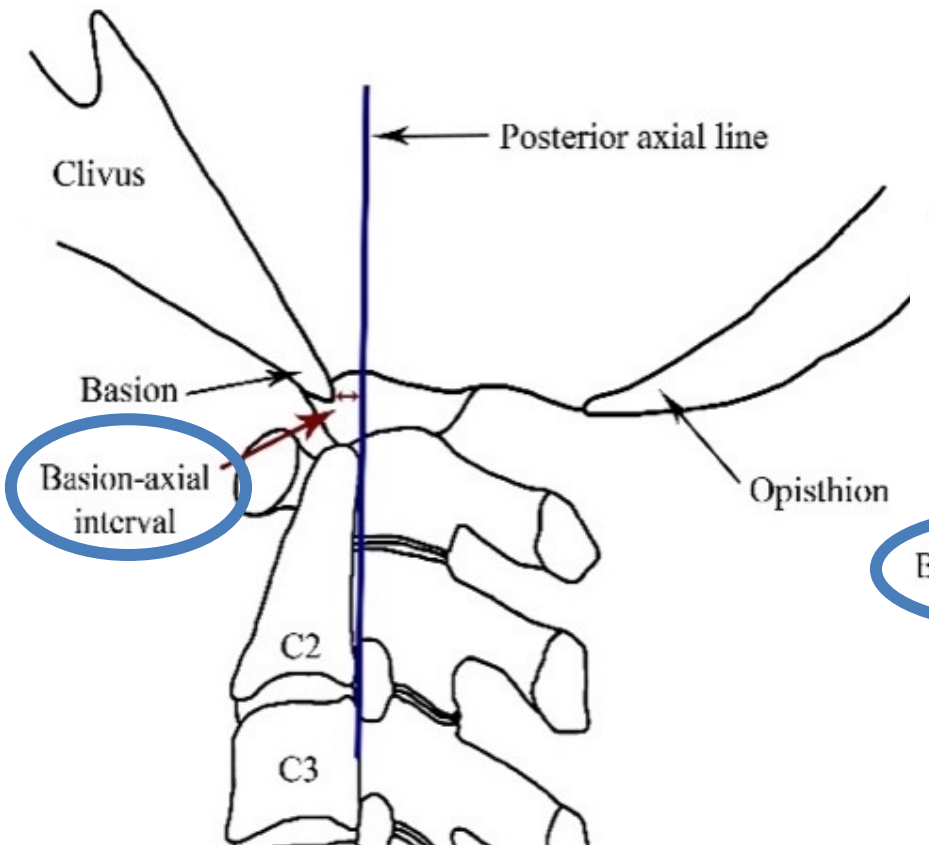

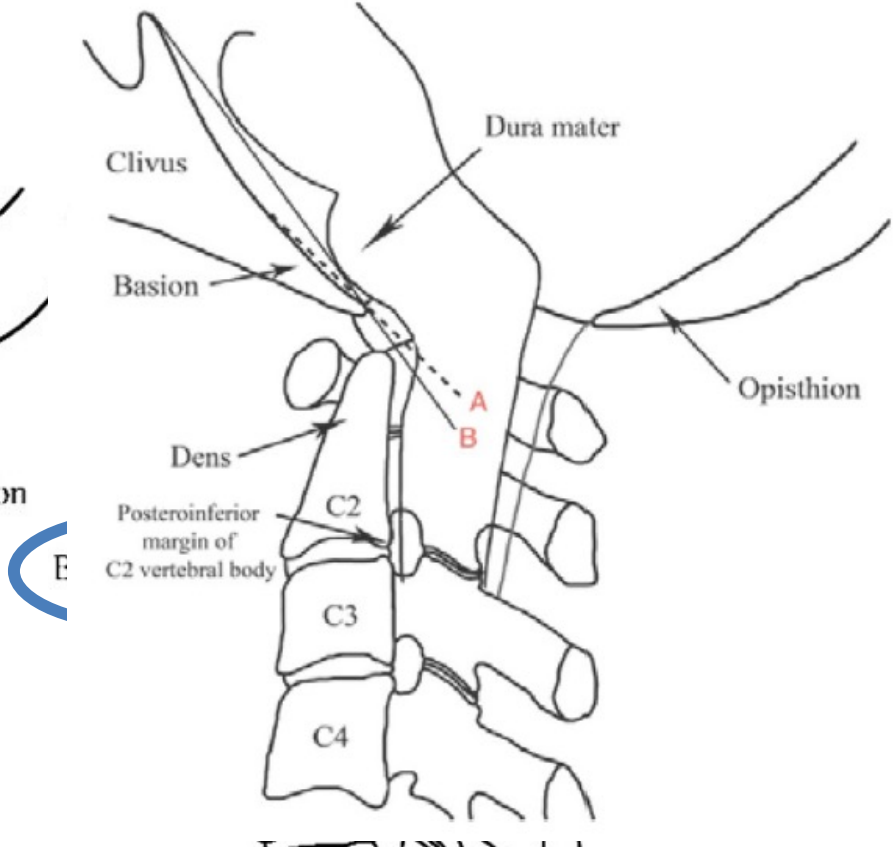

Most Common CCI Measures

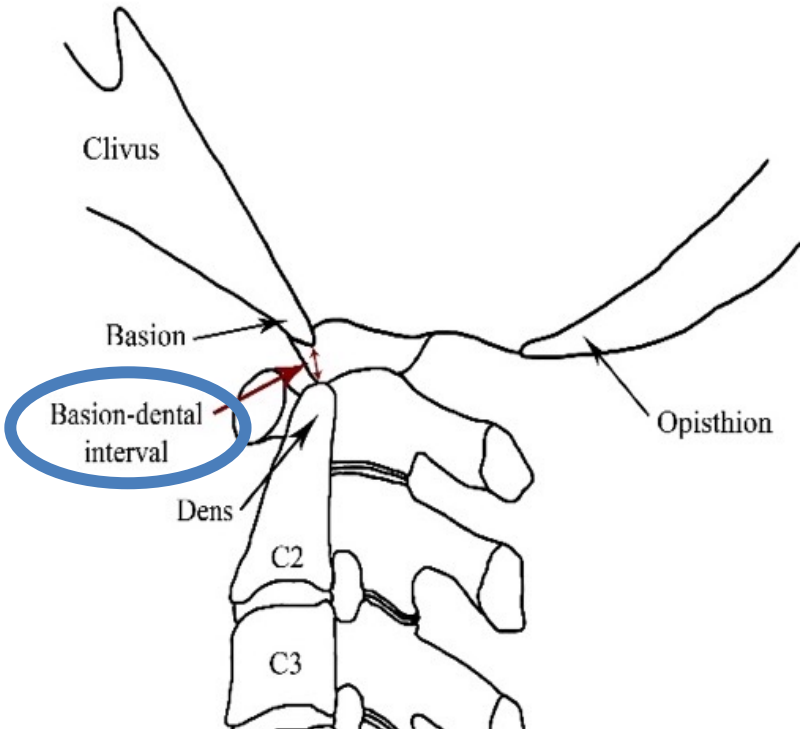

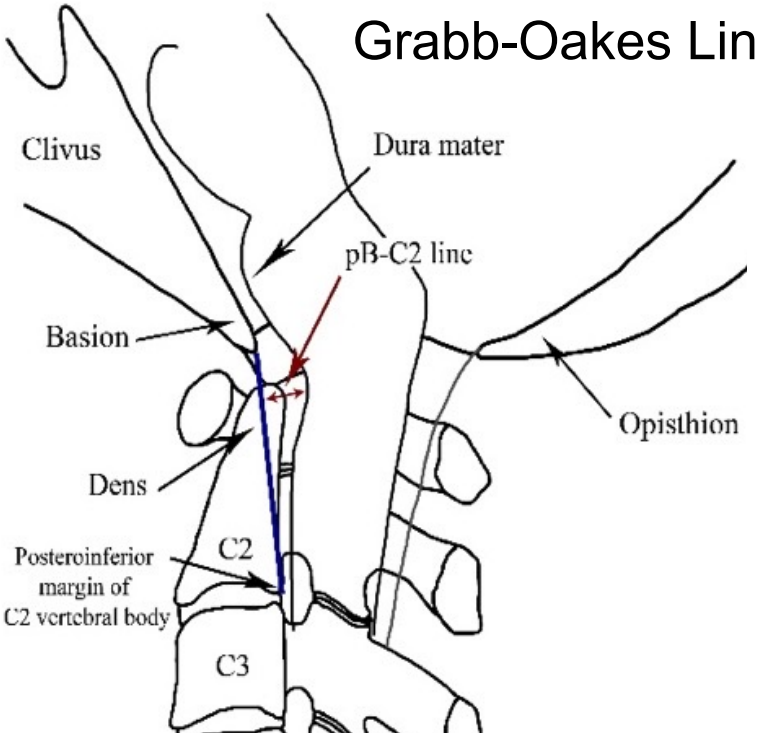

Existing Normative Values

BAI	Norm
Flexion	Unclear
Neutral	**<12mm**
Extn	Unclear

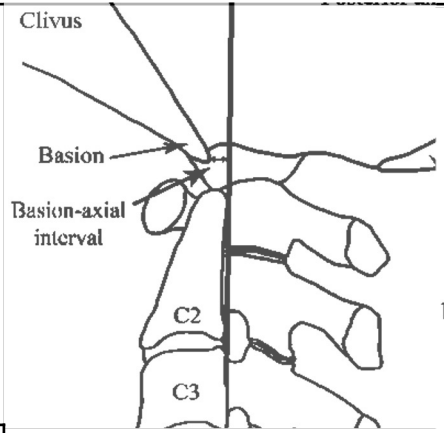

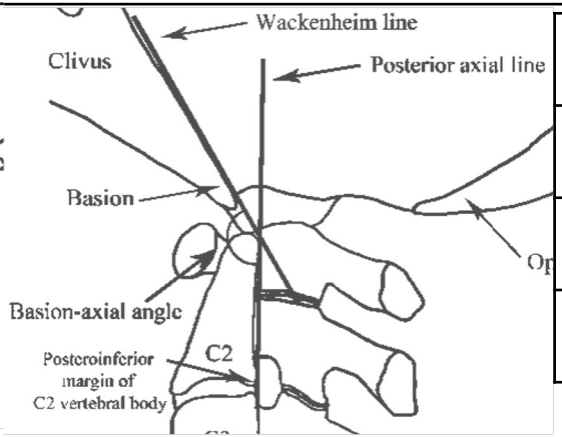

BAA	Norm
Flexion	Unclear
Neutral	**145-160º**
Extn	Unclear

BDI	Norm
Flexion	Unclear
Neutral	**<8.5-12mm**
Extn	Unclear

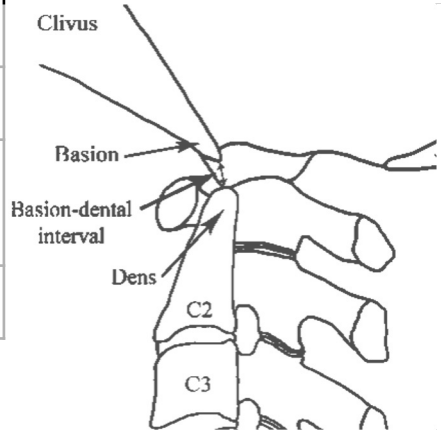

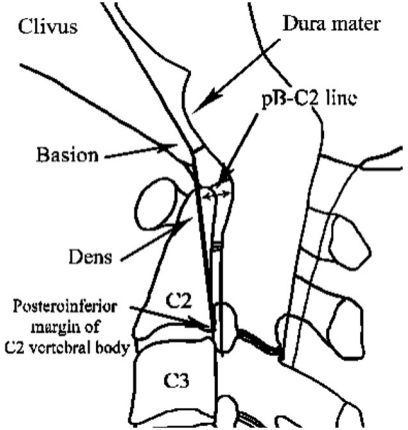

GOL	Norm
Flexion	Unclear
Neutral	**≤9mm**
Extn	Unclear

Methods

University of Sydney HREC Approval #2020/284

- **50 consecutive sets** of upright dMRI images, in neutral, maximal flexion and maximal extension of adult clients who were referral for suspected head or neck injuries
- Whiplash associated disorder, rheumatological conditions of the craniocervical spine or a hereditary disorder of connective tissue were **excluded**
- Images taken at a medical diagnostic imaging centre in NSW, Australia
- All measurements were performed by a neurosurgeon and radiologist on a medical imaging viewer (Voyager PACS Intellirad Solutions Pty Ltd, Australia)

Schematic to MRI images

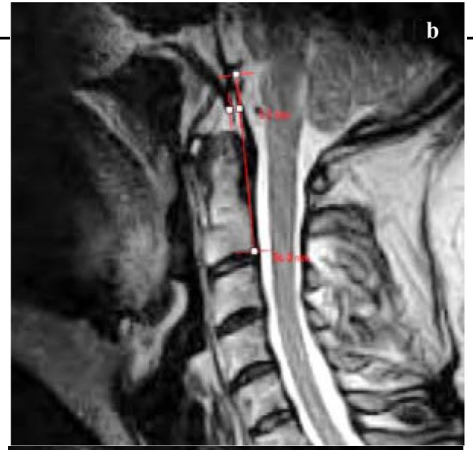

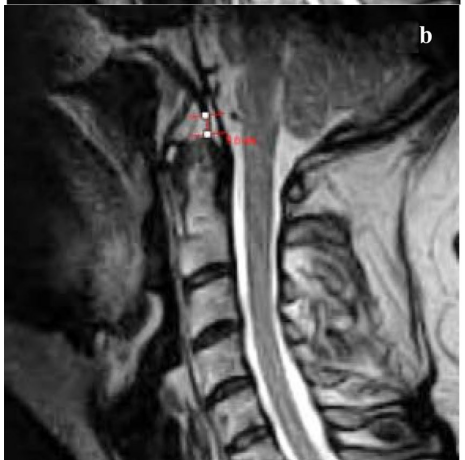

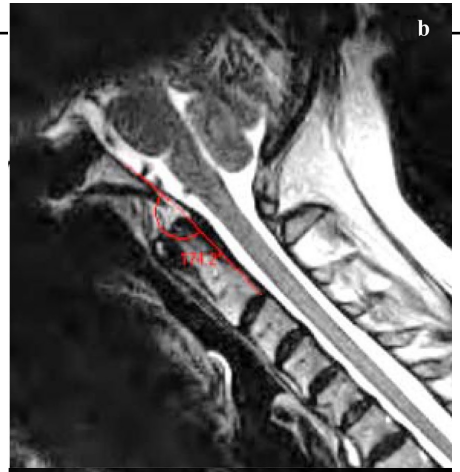

Methods

MACQUARIE University

- Inter-tester reliability was calculated for the first 20 participants. If not acceptable (i.e. < 0.7), the assessors would meet to refine the protocol and remeasure the scans and ICCs would be recalculated.
- Paired t-tests and Pearson's correlation coefficients were undertaken
- We set statistical significance level at $p \leq 0.005$ using Bonferroni correction to account for the multiple hypotheses and to minimize type 1 errors.

Results

Sample Demographics = 25 female and 25 male sets.

Age: 41.2 years (±9.7, range 24–69), no difference between sexes.

All data were normally distributed.

The reasons for referral for udMRI were:

- 72% cervical radiculopathy
- 24% neck pain
- 4% cervical myelopathy

Reference Values

BAI	Reference
Flexion	5.5 ± 4.8mm
Neutral	4.7 ± 4.2mm
Extn	3.2 ± 3.8mm

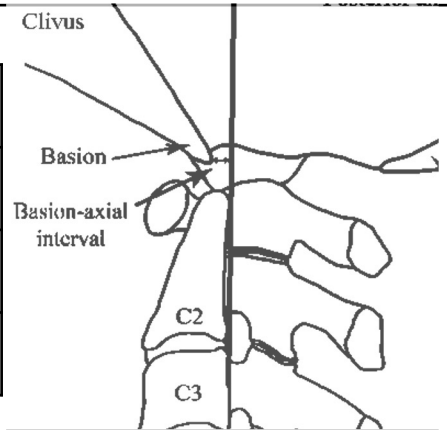

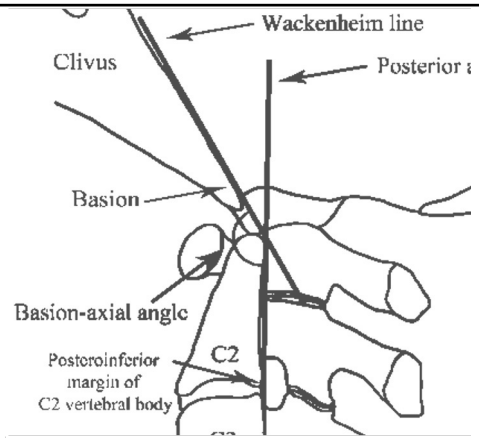

BAA	Reference
Flexion	145.8 ± 19.6
Neutral	148.6 ± 20.6
Extn	161.4 ± 22.2

BDI	Reference
Flexion	5.0 ± 3.2mm
Neutral	5.0 ± 3.0
Extn	5.6 ± 3.2

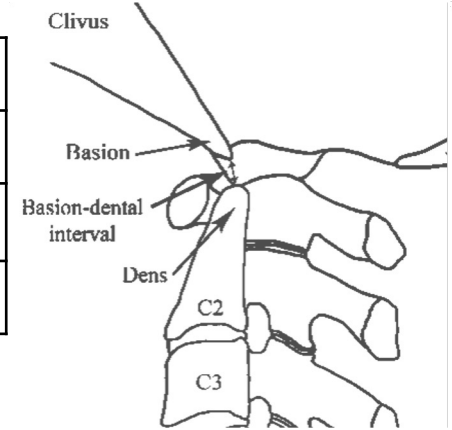

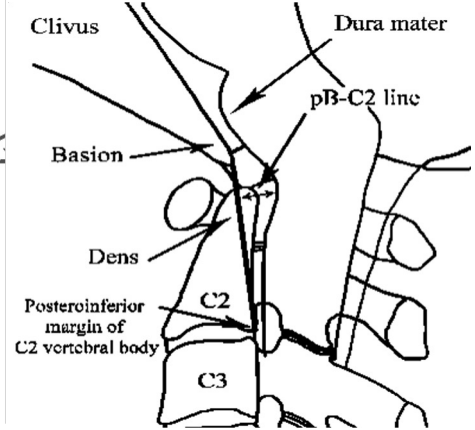

GOL	Reference
Flexion	7.2 ± 3.4mm
Neutral	7.2 ± 3.0
Extn	5.9 ± 3.2

Strengths & Limitations

MACQUARIE University

- ✓ Largest study to investigate reference CCI measures in different positions using udMRI, with participants across a wide age range and of both sexes equally.
- ✓ Statistical significance level at $p \leq 0.005$ accounting for family-wise error.
- ? Retrospectively sourced data
- ? Incepted participants had symptoms related to pain or paresthesia for which their craniocervical region was imaged, constituting a possible selection bias.

Future studies should incept a cervical symptom-free cohort from which normative data and consequent cut-off criteria using udMRI can be determined.

Key Messages & Future Directions

MACQUARIE University

- This study provides reference values for four commonly used radiological measures used to assist in the diagnosis of craniocervical instability.
- Using standardised and detailed protocols with high resolution imaging will aid accurate diagnosis (especially for more junior medical professionals)
- Once normative value ranges are established, we have a role in correlating these imaging findings with cervical special tests (e.g. sharp-purser test, transverse ligament stress test)

Thank you

Research Review – paper 3

Sharon Hennessy

frontiers | Frontiers in Medicine

TYPE Hypothesis and Theory
PUBLISHED 18 January 2023
DOI 10.3389/fmed.2022.1072764

Check for updates

OPEN ACCESS

EDITED BY
Cheryl Maier,
Emory University, United States

REVIEWED BY
Petra Klinge,
Neurosurgery Clinic, Nepal
IG Putu Suka Aryana,
Udayana University, Indonesia

*CORRESPONDENCE
Leslie N. Russek
Lrussek@clarkson.edu

SPECIALTY SECTION
This article was submitted to
Translational Medicine,
a section of the journal
Frontiers in Medicine

RECEIVED 17 October 2022
ACCEPTED 29 December 2022
PUBLISHED 18 January 2023

CITATION

Presentation and physical therapy management of upper cervical instability in patients with symptomatic generalized joint hypermobility: International expert consensus recommendations

Leslie N. Russek[1,2]*, Nancy P. Block[3], Elaine Byrne[4], Susan Chalela[5], Cliffton Chan[6], Mark Comerford[7,8], Nicole Frost[9], Sharon Hennessey[10], Ann McCarthy[4], Leslie L. Nicholson[11], Jason Parry[4,12], Jane Simmonds[4,13], Patricia J. Stott[14], Lucy Thomas[15], Julia Treleaven[7,15], Wendy Wagner[16] and Alan Hakim[12,17]

Presentation and Physical Therapy Management of Upper Cervical instability in Patients with Symptomatic Generalized Joint Hypermobility: International Expert Consensus Recommendations

Presented by Sharon Hennessey
In association with Australian contingent on the below paper.

Russek Leslie N., Block Nancy P., Byrne Elaine, Chalela Susan, **Chan Cliffton**, **Comerford Mark, Frost Nicole, Hennessy Sharon**, McCarthy Ann, Nicholson Leslie L., Parry Jason, Simmonds Jane, Stott Patricia J., **Thomas Lucy, Treleaven Julia**, Wagner Wendy, Hakim Alan

Frontiers in Medicine, VOLUME 9,YEAR 2023

© 2023 Sharon Hennessey

ASSESSMENT STEPS:

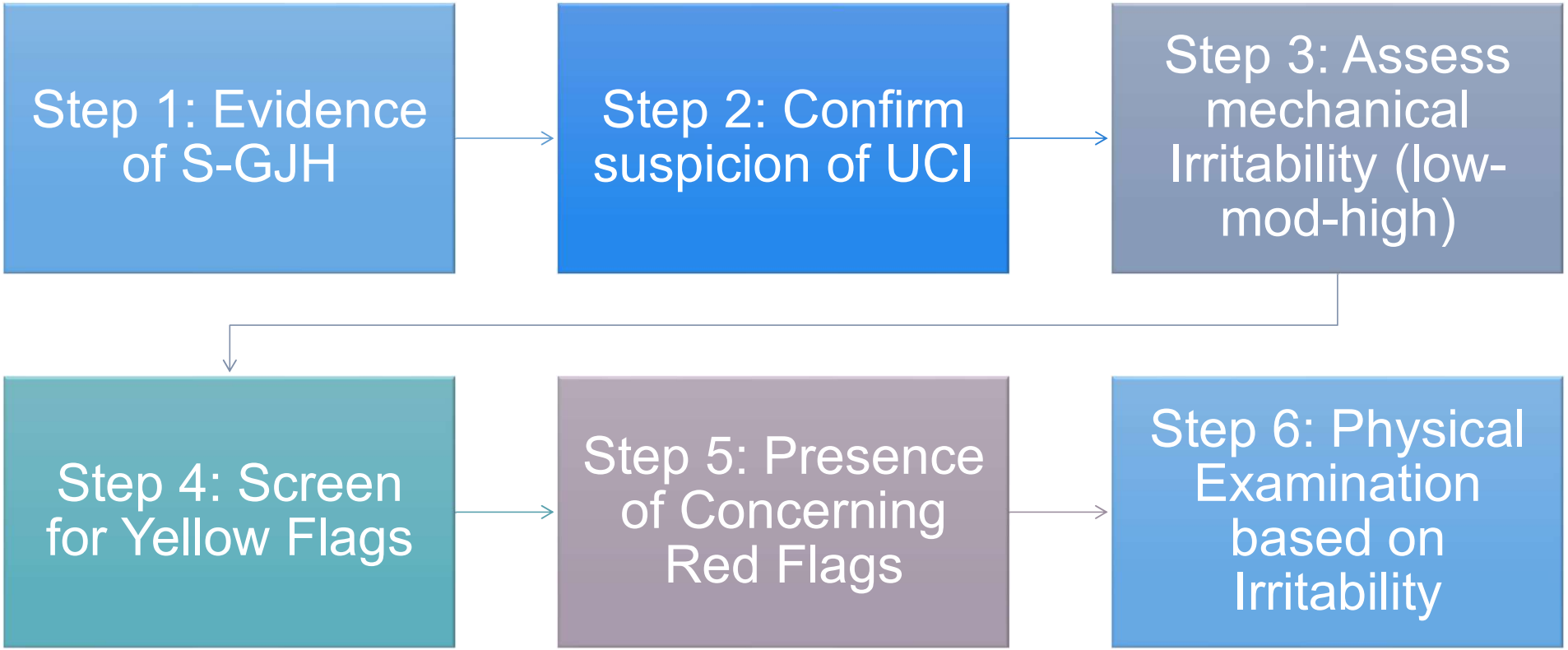

© 2023 Sharon Hennessey

DIFFERENTIAL DIAGNOSIS:

- Overlapping and co-existing with other conditions that are also seen more commonly in the symptomatic hypermobile cohort
  - POTS (Postural Orthostatic Tachycardia Syndrome)
  - MCAS (Mast Cell Activation Syndrome)
  - Migraine
  - Cervicogenic Headache
  - Vestibular issues
  - Neurological conditions
  - FND (Functional Neurological Disorder)
  - Post concussion syndrome
  - Tethered cord
  - Idiopathic intracranial hypertension (IIH)
  - Eagle Syndrome
  - Tarlov cysts
  - WAD (Whiplash Associated Disorder)
  - CSF (Cerebro-spinal fluid) leak
  - Chiari malformation

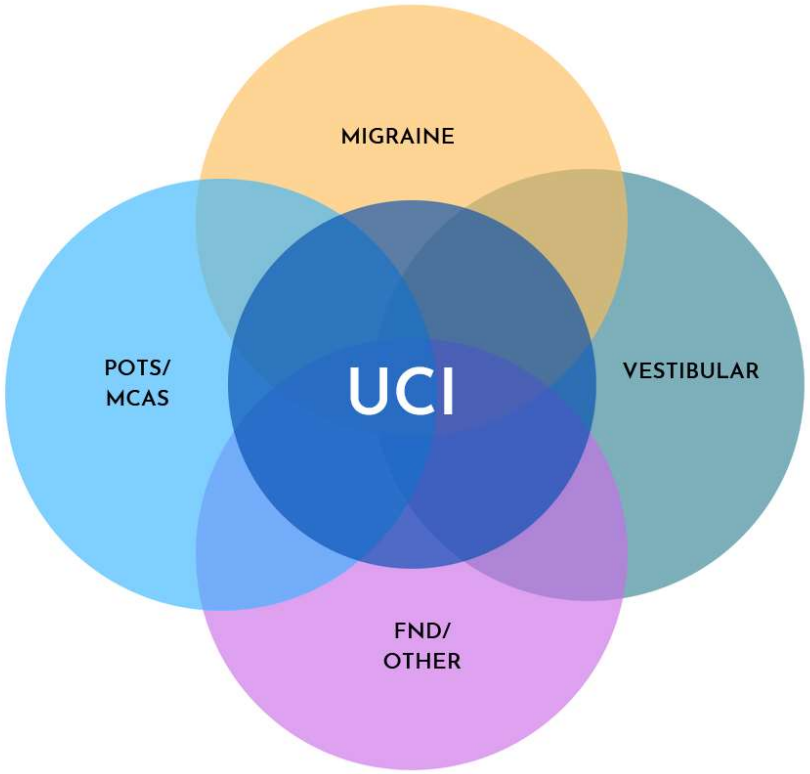

© 2023 Sharon Hennessey

1. Condition is Severe
2. Condition is easily flared and is disproportionate compared with provoking insult or activity
3. Prolonged time to calm after flare – both pain and other symptoms (eg, nausea, dizziness, other neurological symptoms

- Can be delayed response
- Often variable over time

© 2023 Sharon Hennessey

Step 3: Assess mechanical Irritability (low-mod-high)

Essential step in determining what Physical Examination is safe

SIGNS/SYMPTOMS	HIGH IRR 	MODERATE IRR 	LOW IRR
Neurological symptoms	• Severe fatigue • Swallowing/voice changes • Visual disturbances • Tinnitus • Co-ordination & balance issues • Severe nausea • Cranial nerve signs • Drop attacks • Pseudo seizures	• Nausea • Dizziness • Visual Disturbances • Swallowing/voice • Fatigue • More Neuro signs during flare	• Nausea • visual ocular integration disturbed • Fatigue • More Neuro signs during flare
Flared by	• Upright against gravity • Neck movement	• Rapid or unexpected perturbations • Travel in car • Prolonged postures	• Activity outside of normal pacing “bubble” • Combinations of forces/increase time exposed to those listed for moderate
Functional ability	• Bed or chair bound • Upright for short periods only	• Partially functional • Rests after upright time	• Relatively normal function

SIGNS/SYMPTOMS	HIGH IRR	MODERATE IRR	LOW IRR
Cervical ROM (F/ROT/LF)	• Restricted ROM • Global Muscle guarding • Fear of movement	• Mild restriction ROM • Muscle guarding on a segmental level	• Range normal or hypermobile
Cervical EXT	• Minimal	• Reluctant	• Able but poor control
Reaction to hands on mobilisation	• Symptoms worsen	• Often craved and relieving • Balance with stability or taping (beware of taking away all compensations)	• Craved and relieving
Flare intensity	• Neurological & MS symptoms flare • Unable to be upright • Needing Cervical hard/soft collar and/or bed rest to ease symptoms	• MS & mod neuro system flared • Moderate neurological symptoms including nausea, dizziness, swallowing (worse than baseline)	• MS symptoms flare • Mild neurological symptoms including nausea, dizziness when
Response to rehab	• Direct Neck based rehab limited	• Neck based rehab tolerated very slowly	• Neck based rehab tolerated but slower than normal population

© 2023 Sharon Hennessey

- Psychosocial symptoms are risk factors
- Ask sincerely regarding past-trauma, anxiety and general mood
  - Best option at this point in the professional relationship
- Standardized Questionnaires
  - beware of opening a can of worms with regard to medical and other trauma
- Onward referral but continue with assessment

© 2023 Sharon Hennessey

Step 4: Screen for Yellow Flags

Step 5: Presence of Concerning Red Flags

Stable symptoms; Neuro/vascular/cardio specialist consult completed previously	• Conservative management
Progressing symptoms; Out of your scope; Something doesn't add up	• Non-urgent referral • Continue cautious conservative management
Stroke symptoms; Sudden onset thunderclap headache; artery dissection signs	• Discontinue session • Urgent referral to A&E • Send letter with clear list of concerns

© 2023 Sharon Hennessey

PHYSICAL EXAM BASED ON IRRITABILITY:

Step 6: Physical Examination based on Irritability

Highly Irritable

- Observational based tests
  - Breathing pattern
  - Posture
  - Reluctance to move neck *
  - In-coordination *
  - Facial asymmetry
- Neurological testing *
  - Cranial nerve II,IV,VI (eye movements) & X, XII *
  - Hoffman, Babinski, clonus *
  - Ataxia or fine motor dyscoordination *
- Csp – controlled ROM – Rot, Flex
- Palpation (supine)
  - Assess muscle spasm especially sub-occipitals, SCM, LS, UT
  - Very gentle compression ?

Moderately Irritable

- As for Highly irritable +
- Thoracic ROM and quality
- Scapula muscle strength & motor control
- TMJ
- DNF recruitment & cervical stabiliser motor control
- Sensorimotor tests – eye-head co-ordination and eye tracking
- Csp proprioception
- Csp ROM
- Palpation (supine)
  - Grade III- unilateral PA
  - Csp distraction or compression

Mildly Irritable

- As for high and moderately irritable +
- Alar lig test is provocative/Modified sharp-purser relocation test ?? Our UCI team do not recommend
- Neural/dural testing
- Sensorimotor tests with increased complexity e.g. head turning and focus side to side while walking
- Csp & UL strength testing
- Palpation (supine):
  - Grade III/IV PAIVM Rot or LF //gives indication of local laxity and check for end feel
  - Csp distraction or compression

© 2023 Sharon Hennessey

TREATMENT (based on irritability):

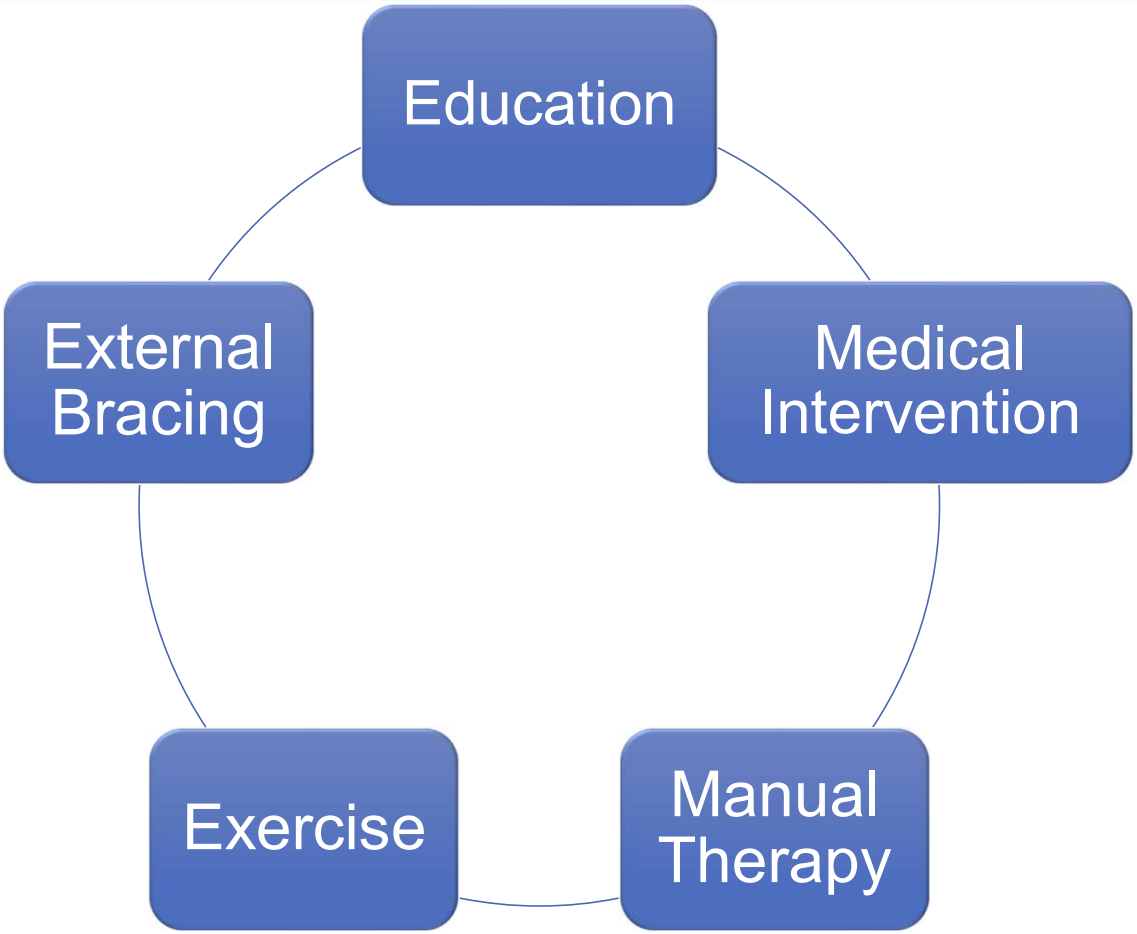

© 2023 Sharon Hennessey

EDUCATION:



- **High irritability:**
  - Use of hard collar
  - Keeping head in midline for self-care activities
    - Hip hinge to brush teeth
    - Belly button facing who you are talking to
    - Getting out of bed, turning trunk and head together
    - Being aware of instilling fear of movement so will be variable for other levels of instability
  - Avoiding Valsalva
  - Pacing advice
  - Flare management
- **Moderate:**
  - Use of soft collar and environmental supports
  - Low intensity functional activities e.g. push/pull/drive/squat/computer use
  - When to limit movement and when to increase movement
- **Mild**
  - Ergonomic and moderate level functional activities e.g. lifting/work
  - Sport specific advice – avoidance of contact sports
  - How to self-monitor movement and patterns of movement – including neck & shoulder positions

© 2023 Sharon Hennessey

EXTERNAL BRACING:

- Environmental support: travel pillow; neck peanut pillow; high backed chair
- Soft Collar
  - Focus on symptom management to allow more time upright and for community/social interaction e.g. passenger in car travel
  - Can give external postural feedback
  - Teach postural reversals within collar to be performed regularly
  - Recommended brands: Protecta collar (Medi)
- Hard Collar:
  - Aspen Vista (OPC);
  - Miami J select (Ossur)
  - Optimised by P&O if fit is poor
- Future: 3D printed collars

© 2023 Sharon Hennessey

EXERCISE : THE BEST OPTION

- Posture and head position “goldilocks” amount of correction
- Breath control and learning to release tension in thorax and anterior neck
- Motor control
  - outside of the upper neck at first
  - then Upper Cx area
- Longitudinal loading with weight on head
  - Start with 300g for 15 seconds*3 and build weight and time
  - Integrate with rotation/walking/arm exs
  - Proprioceptive and functional strength of upright
- Eye tracking and sensori-motor control with laser
- Shoulder/arm strength with light weights
- Avoid “back & down” scapula retraining
  - UT/LT/SA combo for repositioning
- CV endurance
  - Recumbent bike

© 2023 Sharon Hennessey

MANUAL THERAPY:

- Based on irritability
- Treat Supine (don't go straight to prone)
  - Monitor patient eyes/facial expression/skin colour
  - Eliminate effect of gravity increasing extension
- Don't push hard if no end feel
- Don't release all areas at the same time
  - TMJ/upper Csp/lower Csp/sh/rib
  - joints/muscles
- Start cautiously and build up over a few treatments noting effects
- Beware – client who reports huge flare from therapist "who did not know what they were doing"

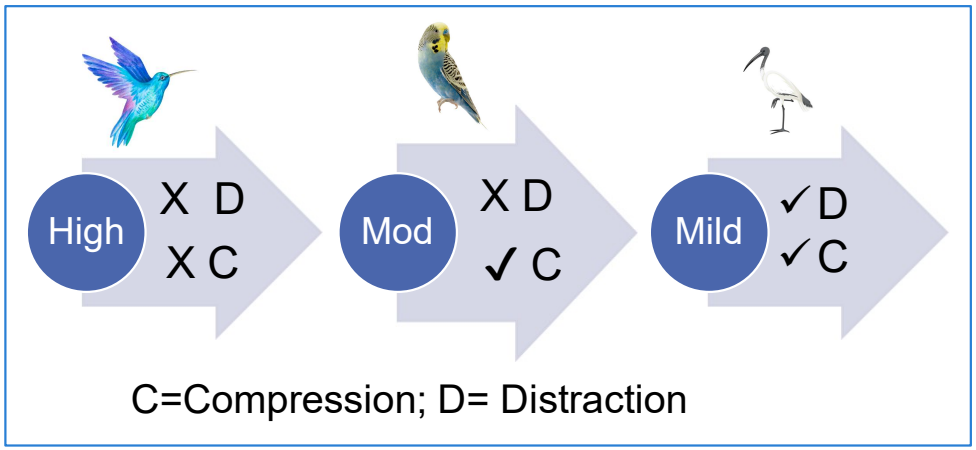

Attend "How to session" with Mark Comerford tomorrow.

© 2023 Sharon Hennessey

MEDICAL INTERVENTION:

- Management of co-morbidities including pain, POTS, fatigue, MCAS etc
- Upright MRI (+F/E) or supine CT (+Rot) or supine MRI (+F/E)
  - Understanding and skill with interpretation still developing
- Cervical spine prolotherapy/PRP
- Halo brace trial for 3 months and note effects on symptoms
  - including neurological and POTS symptoms rather than pain
  - If successful trial → Cervical fusion may be warranted

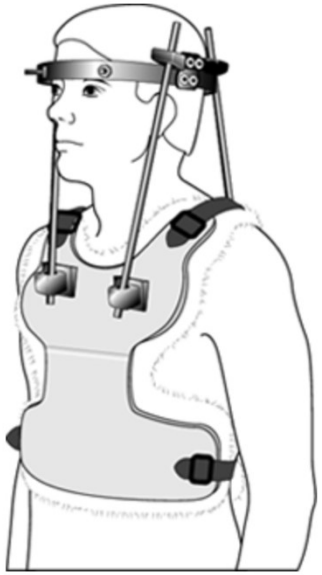

© 2023 Sharon Hennessey

CONTACT

SHARON HENNESSEY

Email me at

reception@notjustbendy.com

Follow me on Facebook

www.facebook.com/Notjustbendy/

Visit my website

www.notjustbendy.com

© 2023 Sharon Hennessey

Practical management strategies | Resources

Saturday 13.40-14.10 (Musculoskeletal C)

How to clinically assess and plan a movement rehabilitation strategy for people with mild to moderate upper cervical instability

Mark Comerford